



# Tibial Tuberosity Transposition Tool Technique in Combination with Distal Femoral Lateral Closing Wedge Osteotomy for Patellar Luxation Treatment in Five Dogs

Eloy Henrique Pares Curuci<sup>1</sup> Ana Carolina Valentim Hespanha<sup>2</sup> Luis Gustavo Gosuen Gonçalves Dias<sup>2</sup>  
Bruno Watanabe Minto<sup>2</sup>

<sup>1</sup>Ortopediavet—Eloy Curuci and team, São Paulo, Brazil

<sup>2</sup>Department of Veterinary Clinic and Surgery, School of Agricultural and Veterinary Sciences, São Paulo State University, Jaboticabal, São Paulo, Brazil

**Address for correspondence** Ana Carolina Valentim Hespanha, DMV, Department of Veterinary Clinic and Surgery, School of Agricultural and Veterinary Sciences, São Paulo State University, Jaboticabal, Via de Acesso Prof. Paulo Donato Castellane s/n, CEP 14884-900, São Paulo, Brazil (e-mail: ana.hespanha@bol.com.br).

VCOT Open 2023;6:e52–e55.

## Abstract

Medial patellar luxation is a multifactorial condition resulting from a misalignment of the stifle extensor mechanism. Several techniques have been described for correcting this condition, depending on the specific morphological changes identified. This case series describes the combination of tibial tuberosity transposition tool techniques and distal lateral femoral closing wedge osteotomy in the treatment of dogs with medial patellar luxation. A combination of these two techniques was used in five dogs with varying degrees of medial luxation of the patella resulting from distal femoral varus and less than 20 degrees distal external torsion of the tibia. The combination of techniques allowed the alignment of the stifle extensor mechanism and corrected medial patellar luxation in all dogs. Radiographic bone union occurred in all dogs, with a mean time of  $30 \pm 2$  days for tibial osteotomy and  $48 \pm 16$  days for the femur. There was no recurrence of patellar dislocation, and no complications developed in any animal during a 1-year-long observation period. This case series demonstrates that the combination of tibial tuberosity transposition tool techniques and distal lateral femoral closing wedge osteotomy can be an effective treatment for medial patellar luxation associated with distal femoral varus with external tibial torsion less than 20 degrees.

## Keywords

- ▶ misalignment
- ▶ femoral varus
- ▶ external tibial torsion
- ▶ medial patellar luxation
- ▶ dog

## Introduction

Medial patellar luxation is one of the most common causes of pelvic limb lameness in dogs.<sup>1</sup> It has been associated with complex and multifactorial etiopathogenesis, where patellar luxation is merely the clinical manifestation of misalignment of the stifle extensor mechanism, resulting from several anatomical, morphological and functional changes.<sup>2,3</sup>

Current surgical treatments are based on the recognition and grading of bone and/or soft tissue deformities, with the severity of medial patellar luxation characterized by a four-degree classification scheme developed by Putman<sup>4</sup> and later adapted for veterinary use by Singleton.<sup>5</sup> This is followed by careful planning of the combination of techniques to align the stifle extensor mechanism and stabilize the patella.<sup>3</sup> The aim of lateral distal femoral closing wedge osteotomy (DFO) is to correct femoral varus deviation and potentially correct

received  
March 23, 2021  
accepted after revision  
June 11, 2022

DOI <https://doi.org/10.1055/s-0042-1757347>.  
ISSN 2625-2325.

© 2023. The Author(s).  
This is an open access article published by Thieme under the terms of the Creative Commons Attribution License, permitting unrestricted use, distribution, and reproduction so long as the original work is properly cited. (<https://creativecommons.org/licenses/by/4.0/>)  
Georg Thieme Verlag KG, Rüdigerstraße 14, 70469 Stuttgart, Germany

the anatomic lateral distal femoral angle (aLDFA) in line with preoperative plans.<sup>6</sup> Additionally, the tibial tuberosity transposition tool technique (4T), described by Petazzoni,<sup>7</sup> for the correction of tibial torsions, gives satisfactory results and has the advantage of requiring only a partial tibial osteotomy, thus favouring bone consolidation and reducing the implants needed.<sup>7-9</sup> The combination of both techniques has not previously been reported. This case series describes the clinical and radiographic results of the combination of 4T and DFO in correcting medial patellar luxation in five dogs.

## Treatment

The surgical procedures were performed between 2019 and 2020 at a centre specializing in veterinary orthopaedic surgery. The inclusion criteria were toy and small dog breeds (< 10 kg) with medial patellar luxation and distal femoral varus deformity. The exclusion criteria were femoral rotation and internal rotation of the tibial tuberosity (when comparing the proximal and distal aspects of the tibia) greater than 20 degrees and the presence of tibial valgus deviation.

The degree of distal femoral varus (aLDFA) was assessed radiographically using both craniocaudal and caudocranial projections, and the absence of femoral torsion was assessed using mediolateral projections and axial femoral projections as described by Brower and colleagues.<sup>6</sup> External torsion of the tibial tuberosity was evaluated on orthogonal (craniocaudal and mediolateral) radiographs of the tibia, including the stifle and talocrural joints, as described by Petazzoni.<sup>7</sup> The magnitude of tibial torsion was estimated by comparing the proximal portion of the tibia in the craniocaudal projection with reference images of the internal/external tibial rotation table developed by Petazzoni.<sup>7</sup> Torsion was defined from the proximal to the distal direction. Thus, external tibial torsion is expected in cases of medial patellar dislocations. All radiographs were obtained under general anaesthesia. Computed tomography (CT) was used as an evaluation method, when available.

All procedures were performed by the same surgeon. Corrective femoral osteotomy was performed as described by Brower and colleagues<sup>6</sup> through a closed wedge osteotomy with a lateral base and an intraoperative jig aid. Rigid fixation was achieved by applying a plate and screws to the lateral surface of the femur.

To correct the external tibial torsion, partial osteotomy of the tibial crest was performed with subsequent application of the 4T device. Translation of the tibial crest to the desired position was performed slowly, thus avoiding iatrogenic fracture of the displaced fragment. Before removing the tool, a Kirschner wire acting as a spacer was inserted at the height of the distal attachment of the patellar tendon. The size of the pin corresponded to the measured distance between the innermost edge of the osteotomized tibial cortex and the outermost edge of the tibial tuberosity cortex. The pin connects the tibial crest and tuberosity. This served as a spacer, maintaining the tibial crest and tibial tuberosity in the desired positions until bone consolidation was complete.

Medial desmotomy and lateral imbrication of the joint capsule were performed in all dogs. None of the dogs had a shallow femoral trochlea. Therefore, trochleoplasties were not performed.

Clinical and radiographic assessments were executed every 4 weeks until bone healing, and a new clinical and radiographic check-up was performed 1 year after the surgical procedure. These re-examinations were done by the same specialist observer.

Radiographic healing was assessed using classification criteria developed by the International Society of Limb Salvage, where scores were defined as follows: 1 = poor union, with less than 25% cure (no evidence of callus), 2 = tight union with 25 to 50% cure, 3 = good bond with cure more than 50 to 75%, and 4 = excellent bond with more than 75% healing.<sup>10</sup> To assess the progress of bone healing, tibial and femoral craniocaudal and mediolateral radiographs were obtained (►Fig. 1).

The clinical assessments included an evaluation of the stifle joint, pain upon hyperextension or pain upon stifle deep palpation, crepitus or recurrence of patellar luxation. Gait was assessed during walking and running to assess the degree of lameness or non-use of the limb. Hindlimb lameness was given a numerical score, with grade 0 = no lameness, grade 1 = weight-bearing with occasional lameness, grade 2 = weight-bearing with frequent but intermittent lameness, grade 3 = continuous weight-bearing lameness, grade 4 = weight-bearing lameness with occasional non-weight-bearing lameness, and grade 5 = non-weight-bearing lameness.<sup>11</sup>

## Results

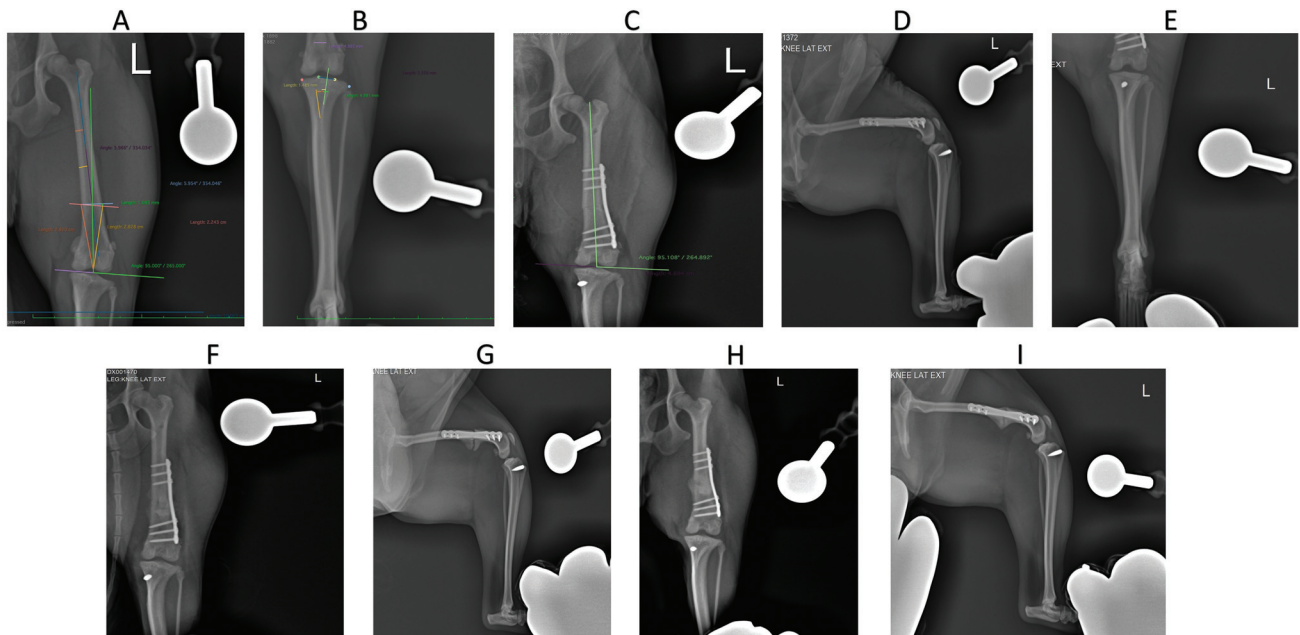
Five dogs met the inclusion criteria. All of the dogs included were small breeds, with an average weight of  $4.72 \pm 1.61$  kg. Most of the dogs were young, with a median age of 2 years (range: 7 months to 4 years) (►Table 1).

Medial luxation of the patella was categorized as grade II (2), III (2), and IV (1), with all cases being the result of distal femoral varus deviation and external tibial torsion less than 20 degrees. Only one patient underwent CT. All others underwent standard radiographs of the femur and tibia. The preoperative mean aLDFA was  $104.7 \pm 2.5$  degrees, and immediately postoperatively, this was  $94.6 \pm 1.04$  degrees. After complete bone healing, aLDFA was measured, with a mean of  $94.4 \pm 1.2$  degrees. The mean preoperative tibial external torsion was  $8 \pm 2.73$  degrees (►Table 1).

Only the lateral plate was used in all dogs for DFO.

The dogs in this case series were reassessed by the clinicians 14, 30, 45, and 60 days after the procedure. At 30 days, all were full weight bearing on the pelvic limbs, with one dog presenting with grade I lameness and the others had none. On the evaluation at 45 days, none of the dogs were lame. In the radiographic assessment of bone consolidation, the mean time for calcifying callus formation was  $30 \pm 2$  days for the tibial osteotomy, and  $48 \pm 16$  days for the femoral osteotomy (score 4).

One year after surgery, no lameness was present in any of the five dogs, and there was no recurrence of patellar



**Fig. 1** (A) Planning for femoral osteotomy showing the anatomical lateral distal femoral angle (aLDFA) measured (aLDFA 95 degrees target); (B) Preoperative planning of the tibial tuberosity transposition tool technique (4T) technique; (C) Postoperative craniocaudal radiograph, with the final aLDFA of 95.108 degrees; (D) Mediolateral radiographic view showing the restoration of the extensor mechanism of the quadriceps with repositioning of the patella; and (E) Craniocaudal view of the tibia showing the position of the pin displacing the tibial crest. Four weeks postoperatively; (F) Craniocaudal radiographic view of the femur and (G) mediolateral radiographic view of the tibia showing partial consolidation in the lateral distal femoral closure wedge osteotomy and total consolidation in the 4T technique. Eight weeks postoperatively; (H) Craniocaudal radiographic view of the femur and (I) mediolateral radiographic view of the tibia showing consolidation in the wedge osteotomy for lateral distal femoral closure and the 4T technique.

dislocation. On radiographies, all implants were in situ with no signs of loosening, and degenerative joint disease was not observed.

**Discussion**

This case series of five dogs with medial patellar luxation showed that the combination of 4T with DFO achieved the intended goal of aligning the stifle extensor mechanism. The patellar instability was due to distal femoral varus and external tibial torsion less than 20 degrees. The combination of treatments resulted in good bone consolidation and full

return to limb function, and there was no recurrence of patellar luxation in any dog.

Postoperative recurrence of patellar luxation is a problem in animals with distal femoral varus after conventional surgical techniques, such as trochleoplasty and transposition of the tibial tuberosity.<sup>2,12</sup> In our cases, the DFO technique allowed a femoral alignment very close to the 95 degrees as planned preoperatively, resulting in a reduction in aLDFA, which was maintained after complete bone union.

The implants used for DFO do not provide interfragmentary compression. Therefore, bone healing occurred secondary to

**Table 1** Summary data of the five dogs with medial patellar luxation treated by the combination of the tibial tuberosity transposition tool technique (4T) and distal femoral lateral closing wedge osteotomy (DFO)

Breed	Sex	Age	Body weight (kg)	Luxation degree (preoperative)	Trochleoplasty	Tibial torsion (degree)	Preoperative aLDFA (degree)	Postoperative aLDFA (degree)	aLDFA after bone healing (degree)
German Spitz	F	1 y	4	IV	No	10	108	95	95
German Spitz	F	7 mo	2.5	II	No	5	104	95	95
Shih-tzu	F	1.5 y	6	II	No	5	102	96	95
Yorkshire	M	4 y	6	III	No	10	101	95	95
Cavalier King	F	9 mo	6	III	No	10	107	95	95

Abbreviations: aLDFA: lateral distal femoral anatomical angle; F, female; M, male.

callus formation. The age of the dogs also favoured rapid bone consolidation and early return to function.<sup>13</sup>

The 4T technique was developed to treat internal or external tibial torsion in animals with grade I or II patellar luxations with tibial external torsion less than 20 degrees.<sup>2</sup> The technique was successful in the presented cases, even with grade III and IV luxations when the patellar displacement was secondary to external tibial torsion and excessive distal femoral varus deformity.

Although the 4T technique was described in 2015, few studies have evaluated and demonstrated its results, and for this reason, the most recent reviews regarding the treatment of medial patellar dislocation are not included in the treatment portfolio.<sup>3,14</sup>

The complex anatomy of misaligned tibia–femur units, as in our cases, required three-dimensional reconstruction using CT or well-positioned radiographs.<sup>15</sup> Although CT imaging seemed superior for preoperative planning, we could only perform CT scans on one of the five dogs. However, we do not believe this affected the final results. Nevertheless, accurate preoperative measurements are of utmost importance to tailor and optimize treatment using an appropriate combination of osteotomy techniques.

Recurrence of patellar luxation is one of the most reported complications, and according to some studies, this is more likely to occur following bone realignment techniques when trochleoplasty is not performed.<sup>16,17</sup> However, in our five cases, correcting rotational misalignment through osteotomies alone without trochleoplasty was successful. This is in accordance with Brower and colleagues<sup>6</sup> and Petazzoni,<sup>7</sup> who did not observe recurrence with DFO or 4T alone. The main limitation of our study is the small number of cases. However, the absence of any recurrence of luxation in all five dogs confirmed the importance of correctly aligning the stifle extensor mechanism through a combination of osteotomy techniques.

In summary, we found that the combination of 4T and DFO was successful in treating medial patellar luxation in five dogs with distal femoral varus and proximal external tibial torsion of less than 20 degrees. Good clinical and radiographic results were achieved with early return of limb function, without lameness and complete osteotomy healing by 2 months after surgery.

#### Authors' Contributions

E. H. P. C., A.C.V.H., and B.W.M. contributed to the conception of study, study design, data acquisition, data analysis and interpretation. A.C.V.H., L.G.M., and B.W.M. contributed to the data analysis and discussion of results. All authors wrote, revised and approved the submitted manuscript.

#### Conflict of Interest

None declared.

#### References

- Bound N, Zakai D, Butterworth SJ, Pead M. The prevalence of canine patellar luxation in three centres. Clinical features and radiographic evidence of limb deviation. *Vet Comp Orthop Traumatol* 2009;22(01):32–37
- Petazzoni M. Tibial Tuberosity Transposition Tool TTTT® and Technique Manual. 1st edition. Milão, Itália: Massimo Petazzoni Books; 2015:65
- Di Dona F, Della Valle G, Fatone G. Patellar luxation in dogs. *Vet Med (Auckl)* 2018;9:23–32
- Putman RW. Patellar luxation in the dog [Master's thesis]. Ontario, Canada: University of Guelph; 1968
- Singleton WB. The surgical correction of stifle deformities in the dog. *J Small Anim Pract* 1969;10(02):59–69
- Brower BE, Kowaleski MP, Peruski AM, et al. Distal femoral lateral closing wedge osteotomy as a component of comprehensive treatment of medial patellar luxation and distal femoral varus in dogs. *Vet Comp Orthop Traumatol* 2017;30(01):20–27
- Petazzoni M. Tibial tuberosity transposition tool. A novel surgical technique for TTT. In: 17th ESVOT congress 2014, Venice (Italy); 2015:233–238
- Petazzoni M. Surgical treatment of medial patellar luxation in dogs using tibial tuberosity transposition tool. In: 86 SCIVAC International Congress 2015, Rimini (Italy); 2015:474
- Leite J. TTTT as a new surgical approach for the treatment of medial patellar luxation grade 1 and 2: preliminary results of the first 121 cases. In: 5th World Veterinary Orthopaedic Congress ESVOT-VOS- 19th ESVOT CONGRESS 2018. Barcelona, Spain; 2019
- Glaser D, Langlais F. The ISOLS radiological implants evaluation system. In: Langlais F, Tomeno B, eds. *Limb Salvage: Major Reconstructions in Oncologic and Nontumoral Conditions*. Berlin, Germany: Springer; 1991:4–25
- Roy RG, Wallace LJ, Johnston GR, Wickstrom SL. A retrospective evaluation of stifle osteoarthritis in dogs with bilateral medial patellar luxation and unilateral surgical repair. *Vet Surg* 1992;21(06):475–479
- Swiderski JK, Palmer RH. Long-term outcome of distal femoral osteotomy for treatment of combined distal femoral varus and medial patellar luxation: 12 cases (1999–2004). *J Am Vet Med Assoc* 2007;231(07):1070–1075
- Benjamino KP, Petazzoni M. The Fixin Implant System. In: Matthew DB, Karl CM, eds. *Locking Plates in Veterinary Orthopedics*. 1st edition. Wiley-Blackwell; 2018:77–81
- Perry KL, Déjardin LM. Canine medial patellar luxation. *J Small Anim Pract* 2021;62(05):315–335
- Kowaleski MP, Boudrieau RJ, Pozzi A. The stifle joint. In: Tobias KM, Johnson SA, eds. *Veterinary Surgery—Small Animal*. 1st edition. St. Louis, MO: Elsevier Saunders; 2012:906–998
- Linney WR, Hammer DL, Shott S. Surgical treatment of medial patellar luxation without femoral trochlear groove deepening procedures in dogs: 91 cases (1998–2009). *J Am Vet Med Assoc* 2011;238(09):1168–1172
- Cashmore RG, Havlicek M, Perkins NR, et al. Major complications and risk factors associated with surgical correction of congenital medial patellar luxation in 124 dogs. *Vet Comp Orthop Traumatol* 2014;27(04):263–270